

## Is Sonopartogram of Value in Monitoring the Progress of Labor? Observational Study

Ahmed.E.Mohammed, Khaled.M.Salama, Mohammed.A.Elnory and Ali.A.Bendary

Obstetrics & Gynecology Dept., Faculty of medicine, Benha University

E-mail: nadaelsheikh96@gmail.com

### Abstract

**Background:** The First-time mothers and their unborn babies rely heavily on skilled management of labour progression. Vaginal exams (VE) are the gold standard for gauging cervical dilation and foetal head position. The purpose of this research was to examine how useful transperineal ultrasonography (TPUS) is for tracking labour. Methods: Thirty-six first-time mothers were included in this prospective observational research. All of the women were at least 18 years old and carrying a single baby during 37 to 41 weeks' gestation. After doing a transvaginal ultrasound (TPUS), the doctor took notes on the mother's cervical dilatation, the foetal head descent, and the head position of the baby. The results of the VE were compared to these measures. The average age of the participants was determined to be 33 years and 7.4 months. The average body mass index was 27.31.3 kg/m<sup>2</sup>. The average gestational age was 39 weeks and 1 day. There was a favourable connection between the foetal head station as measured by VE and the Head-perineum distance as measured by US (p0.001). There was a favourable connection between the foetal head station as measured by VE and the Head-perineum distance as measured by US (p0.001). Women were more likely to comply with and be satisfied with TPUS (66.7% vs. 38.9% with VE, p 0.001) than males were with VE. In conclusion, TPUS shows potential as a safe and user-friendly method for tracking the development of labour in first-time mothers. Our results show that TPUS measures correlate well with traditional vaginal checks at many time points during childbirth.

**Keywords:** Transperineal Ultrasound; Labor Progression; Cervical Dilatation, Fetal Head Station.

### 1. Introduction

The Digital vaginal examination (VE) is the gold standard for monitoring labour progression all around the globe. VE allows doctors to check for cervical effacement and dilation as well as foetal head descent and position.

However, VE may not offer an accurate evaluation of cervical dilatation, and any discrepancies in the results might make women anxious and reduce their trust in their doctors [2].

In women with preterm labour, repeated VE shortens the latent period and raises the risk of ascending infection and chorioamnionitis [3]. Researchers were urged to study ways to reduce VE occurrences in labour by the National Institute for Health and Clinical Excellence (NICE) [4].

The use of transperineal ultrasonography (TPUS) as an auxiliary aid in labour management has been studied [5].

The accuracy of TPUS in determining cervical dilatation and foetal head position and station has been repeatedly confirmed in scientific studies. In other circumstances, such as preterm labour or early membrane rupture, VE is not desired and authors have proposed employing TPUS alone instead. Pregnant women were more receptive to and preferred TPUS than VE [6, 7].

During labour, foetal and mother vitals are often monitored using a printed chart called a partogram. This sonopartogram has not been extensively used [8], despite the encouraging outcomes that have been proposed.

The purpose of this research was to examine how useful transperineal ultrasonography (TPUS) is for tracking labour.

### 2. Methods Patients:

This The Obstetrics and Gynecology department at Benha University Hospital conducted a prospective observational research on 36 pregnant women admitted to the labour unit. The research was conducted over the course of a year.

The research was approved by the Ethics Committee of Benha University's School of Medicine. Parents gave their signed agreement after being given information about the research and a unique identifier.

Women who met the inclusion criteria had to be first-time mothers, be at least 18 years old, be in the active phase of labour (cervical dilation between 4 and 10 cm), and be carrying a single intrauterine pregnancy that was positioned with the head facing the dorsum of the uterus (vertex presentation).

Women with numerous pregnancies, pregnancies at less than 37 weeks or more than 41 weeks, a non-vertex presentation, a lack of labour, or other obstetric contraindications for a normal vaginal birth were ineligible (NVD).

Naegle's method for estimating the due date (EDD) uses a woman's last menstrual period (LMP) plus seven days and nine months, as well as her age, parity, medical and surgical history, and the number of previous pregnancies she has had.

Second, a thorough physical examination is performed, covering [body mass index, vital signs, an examination of the abdomen and pelvis for signs of a caesarean section, such as malpresentations, macrosomia, placenta previa, a history of caesarean section, and maternal diseases like hypertension, diabetes, liver, or kidney disease].

3. Method of measurement: These women were given the conventional method of monitoring labour, in which the obstetrician would perform VE every 2 hours, recording the cervical dilatation (in centimetres) and head station and position, and then plotting these findings onto a conventional partogram along with the other routine parameters, such as maternal vital data and foetal heart rate. The World Health Organization (WHO) defines foetal head descent (station) as the distance in millimetres between the vertex and the ischial spines (-5 to +5). If a measurement was exactly 0.5 cm, it was rounded up to the closest full centimetre.

The posterior fontanel was used to calculate the foetal head's position relative to a standard 12-hour clock face, with results adjusted to the closest half-hour or full-hour (with 12.00 h representing the occiput anterior position). After each VE, a different examiner used a curved 2D GE Logiq P5 ultrasound machine to conduct TPUS while each were blinded to the other's results. The lithotomy posture, with the patient laying supine, was used for the TPUS procedure. The sagittal view will be used to evaluate cervical dilatation, and the cursor will be positioned on the inner portion of the cervical tissue both anteriorly and posteriorly.

The foetal head perineal distance (HPD) was measured in centimetres to determine the foetal head descent in a transverse view. The HPD is the smallest distance between the outer bony boundary of the foetal skull and the perineum. The foetal head position will be stated in the same 12-hour format as the digital VE, with the foetal spine or orbits serving as the landmark and the occiput as the denominator. The TPUS data was plotted on the sonopartogram, which was developed by Hassan et al (2014).

The ladies received routine obstetric care, with the digital VE being shielded from TPUS data and relied upon for labour management. After the baby was born, the participants were

polled on which of the two evaluation techniques they thought was more accurate.

Justification of Sample Size:

To determine the sample size, we used NCSS PASS 11.0 and a study by Sweed et al. (2020) that found a moderate relationship between foetal head station as determined by VE and HPD as determined by TPUS (Kendall's tau-b ( $\tau_b$ ) = 0.299, 95 percent CI = 0.479 to 0.0863,  $p = .0063$ ) (Pearson rho = .3844 [9]. A high Pearson's correlation ( $r = .8601$ , 95% CI = 0.7493 to 0.9240,  $p .0001$ ,  $r^2 = 0.7396$ ) was reported between VE and TPUS measurements of cervical dilatation. Weighted kappa ( $\kappa_w$ ) = .557, 95% confidence interval (CI) = .362 to .753 indicates considerable agreement between VE and TPUS in determining head position on the face-clock. The two-tailed z test with pooled variance is used as the testing statistic. The 0.0050 cutoff was chosen as the significance threshold for the test. In practise, this approach yields a 0.0039 significance level. Using a two-sided z test at a significance level of 0.05000, the sample size of 36 women is enough to detect a difference of 0.325 between an area under the ROC curve (AUC) under the null hypothesis of 0.5000 and an AUC under the alternative hypothesis of 0.6487. Discrete (on-a-scale) replies make up the data. Between a false positive rate of 0 and 1, the AUC is calculated.

Number crunching:

IBM SPSS Statistics Version 25 was used for data cleaning, coding, and tabulation for the statistical analysis. Each parameter's data type informed the form and analysis of that parameter's data. The Shapiro-Wilk test was used to check for the normality of the data distribution. Mean and standard deviation (SD) were employed as descriptive statistics for numerically regularly distributed data, whereas median and range were used for numerically non-normally distributed data. Frequency and percentage distributions were determined for the non-numerical data. The Chi-Square test, Kappa agreement, and correlation analysis were all a part of analytical statistics, and they were used to investigate the degree of link between two qualitative and quantitative variables. A p-value less than 0.05 at a 95% confidence interval was used to establish significance.

### 3. Results

Researchers found that, on average, their test volunteers were 33.574 years old. Their average body mass index was 27.3+/- 1.3 kg/m<sup>2</sup>. The average gestational age was 39 weeks and 1 day. The APGAR score at 1

minute showed that 94.4% were above 6, while 5.6% were below that threshold.

**Table( 1)** Study participants' demographics and birth information.

Variable		Total subjects (n=36)
Maternal age (years)	Mean $\pm$ SD	33.5 $\pm$ 7.4
	Median (Range)	34.5(20-44)
Maternal BMI (kg/m <sup>2</sup> )	Mean $\pm$ SD	27.3 $\pm$ 1.3
	Median (Range)	27.4(25.1-29.8)
Fetal gestational age (weeks)	Mean $\pm$ SD	39.1 $\pm$ 1.4
	Median (Range)	39(37-41)
APGAR score first minutes, n (%)	>6	34(94.4%)
	<6	2(5.6%)

Body mass index (BMI) and the Apgar score (Appearance, Pulse, Grimace, Activity, and Respiration) measure how healthy a person is. At the time of the examination, after 2 hours, after 4 hours, and after 6 hours, the mean cervical dilatation was assessed by VE,

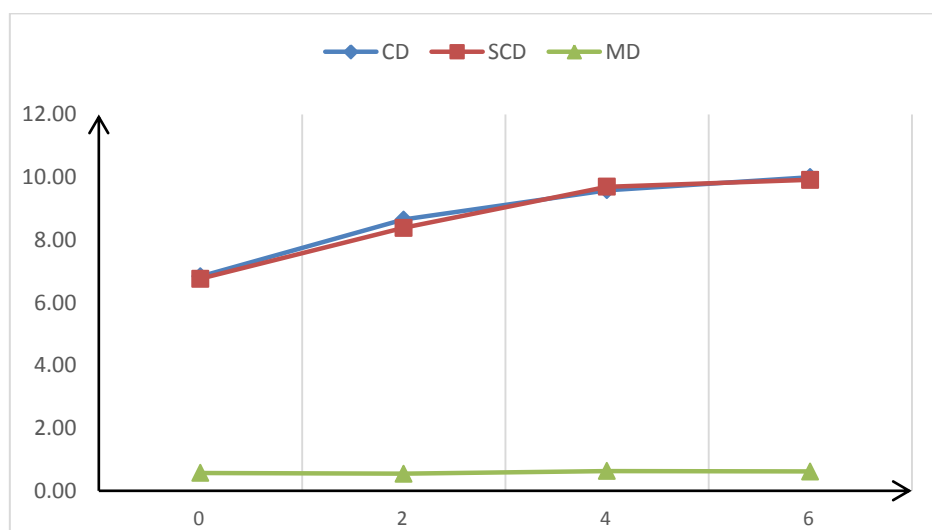
Sonographic CD, and the mean difference between two techniques. There were no statistically significant differences between sonographic and vaginal examinations at any time point. Reviewing Table 2 and Figure 1

**Table (2)** Relation between Cervical dilatation by VE and cervical dilatation by sonography

Variable	CD at examination (n=36)	CD after 2 hours (n=34)	CD after 4 hours (n=19)	CD after 6 hours (n=4)
Cervical dilatation by VE (cm)	6.8 $\pm$ 1.5	8.6 $\pm$ 1.3	9.6 $\pm$ 0.6	10 $\pm$ 0
SCD (cm)	6.8 $\pm$ 1.6	8.4 $\pm$ 1.6	9.7 $\pm$ 0.9	9.9 $\pm$ 0.6
Mean difference (cm)	0.1 $\pm$ 0.6	0.2 $\pm$ 0.3	-0.1 $\pm$ 0.6	0.1 $\pm$ 0.6
Test	0.797	0.841	0.772	0.288
p	0.431	0.090	0.450	0.792

Test=Paired sample t test; \*: Significant  $\leq$ 0.05; VE: Vaginal examination; CD: Cervical

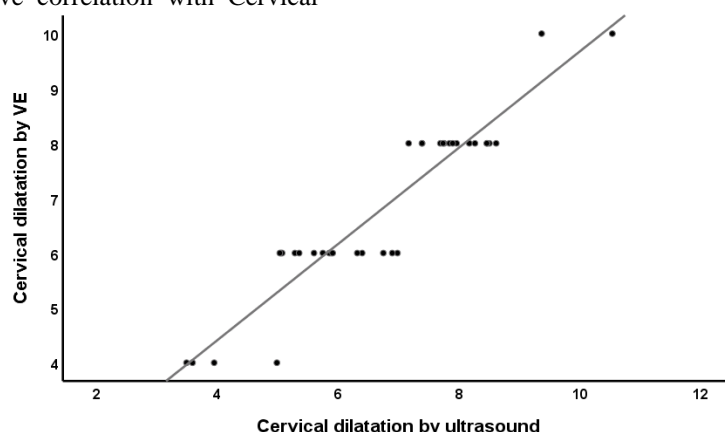
dilatation by VE; SCD: Sonographic cervical dilatation; MD: Mean difference.



**Fig. (1)** Cervical diameter in the studied subjects

Cervical diameter by VE showed a significant positive correlation with Cervical

dilatation by ultrasound (p<0.001). **Figure 2**



**Fig. (2)**Correlation between Cervical dilatation by VE and Cervical dilatation by ultrasound

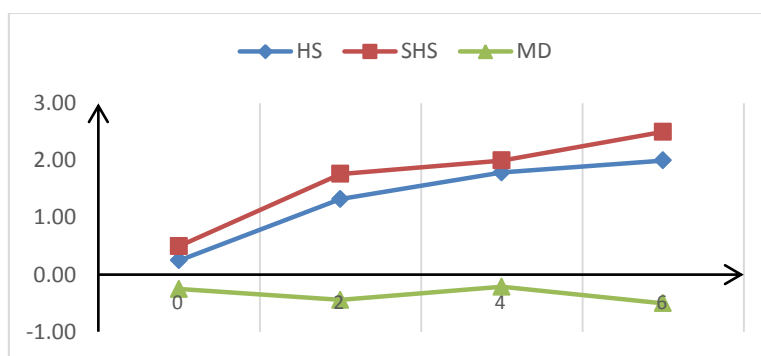
The mean head station by VE, Sonographic HS and mean difference between two methods were measured at time of examination, after 2 hours, after 4 hours and after 6 hours. No significant differences

between the two methods at different periods of time indicating high accuracy of sonographic results compared to vaginal examination. **Table 3** and **Figure 3**

**Table (3)** Relation between Head station by US and fetal head station by VE

Variable	HS at examination (n=36)	HS after 2 hours (n=34)	HS after 4 hours (n=19)	HS after 6 hours (n=4)
Head station by VE	0.3±1.2	1.3±0.7	1.8±0.4	2±0
Head station by ultrasound	0.5±1.5	1.8±0.9	2±0.8	2.5±0.6
Mean difference	-0.3±0.8	-0.4±0.7	-0.2±0.9	-0.5±0.6
Test	1.861	3.447	1.073	1.732
p	0.071	0.090	0.297	0.182

Test=Paired sample t test; \*: Significant ≤0.05; VE: Vaginal examination; HS: Head station; SHS: Sonographic head station; MD: Mean difference



**Fig. (3)** The Preferred Vaginal Examining and Ultrasounding Head Position

There was a favourable connection between the foetal head station as measured by VE and the Head-perineum distance as measured by US (p0.001). Number Four

Head position at various measurement periods revealed high agreement between VE and ultrasound (p0.001), suggesting a strong relationship between the two methods for assessing head position. Table 4

Baby's head position as a function of VE against US, with a correlation shown in Fig.

**Table (4)** Association between VE and US as regards assessment of head position

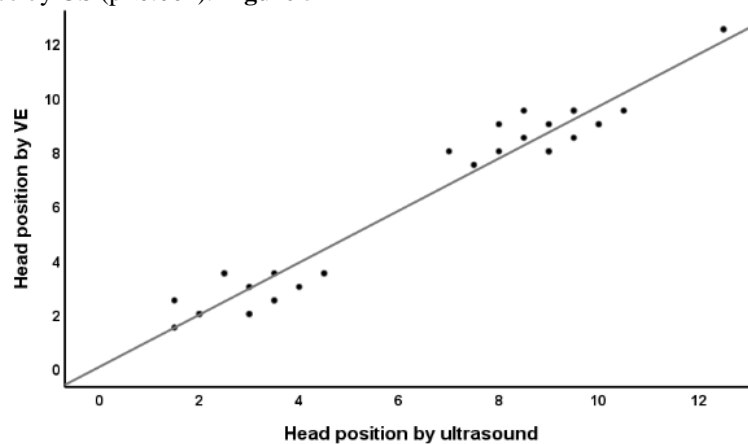
Variable	HP at	HP after	HP after	HP after
----------	-------	----------	----------	----------

		examination (n=36)	2 hours (n=34)	4 hours (n=19)	6 hours (n=4)
Head position by VE	LOT	11(30.6%)	7(19.4%)	2(5.6%)	
	OA	8(22.2%)	1(2.8%)		
	OP	6(16.7%)	13(36.1%)	14(38.9%)	3(8.3%)
	ROT	11(30.6%)	13(36.1%)	3(8.3%)	1(2.8%)
Head position by ultrasound	LOT	9(25%)	6(16.7%)	2(5.6%)	
	OA	10(27.8%)	9(25%)	1(2.8%)	
	OP	7(19.4%)	15(41.7%)	13(36.1%)	4(11.1%)
	ROT	10(27.8%)	4(11.1%)	3(8.3%)	
Test		0.515	0.421	0.734	0.862
p		<0.001*	<0.001*	<0.001*	<0.001*

Test=kappa agreement; \*: Significant  $\leq 0.05$ ; VE: Vaginal examination; HP: Head position; LOT: Left Occiput Transverse; ROT:

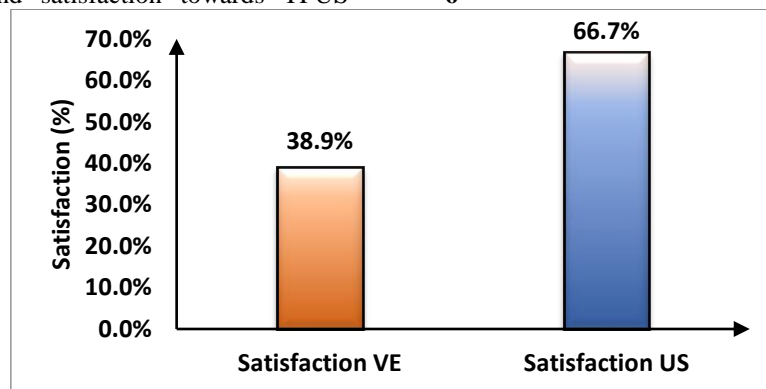
Right Occiput Transverse; OA: Occiput Anterior; OP: Occiput Posterior

Fetal head station by VE showed a significant positive correlation with Head-perineum distance by US ( $p < 0.001$ ). **Figure 5**



**Figure (4)** Correlation between fetal head position by VE vs. US

Women showed significantly more compliance and satisfaction towards TPUS (66.7%) than VE (38.9%), ( $p < 0.001$ ). **Figure 6**



**Fig. (5)** Satisfaction frequencies among the studied subjects

**4. Discussion**

Ultrasound has changed the face of obstetrics by providing a glimpse into the complex events taking place inside the mother's pelvis during childbirth. In particular, transperineal ultrasonography (TPUS) has received a lot of interest as a possible technique for tracking the development of

labour in real time. TPUS is a non-invasive method of monitoring labour progression since it enables the view of cervical dilatation, foetal head descent, and head position [5, 10]. This technique shows potential in obtaining precise measurements by avoiding some of the drawbacks of conventional VE. Consequently, the "sonopartogram," a graphical depiction of

labour progression based on TPUS data, has arisen as a viable alternative to or supplement to the traditional partogram [9].

Sonopartography is gaining popularity, but more research is needed to prove its worth in the clinic. While there has been much research on the precision and consistency of TPUS measurements, nothing has been written about the therapeutic use of sonopartograms.

Therefore, the purpose of this research was to evaluate the efficacy of using ultrasonography to track labour progress.

Thirty-six first-time mothers with singleton pregnancies between 37 and 41 weeks' gestation and who were in active labour with a vertex presentation were included in this prospective observational research. Cervical dilation, foetal head descent, and foetal head position were all measured with TPUS and included into a sonopartogram. The results from VE were compared to these numbers.

The average gestational age of the foetuses in the study was 39.11.4 weeks, and the average age of the mothers was 33.57.4 years with a BMI of 27.31.3 kg/m<sup>2</sup>. At 1 minute, 94.4 percent had an APGAR score of 6 or above, whereas 5.6% had a score of 5 or below. There were no statistically significant discrepancies between VE and sonographic CD measurements of cervical dilatation taken at any of the four time intervals (examination, 2 hours, 4 hours, and 6 hours), demonstrating the superior accuracy of sonographic findings compared to VE. Cervical dilation using ultrasonography was also positively correlated with VE-measured cervical diameter (P 0.001). As with VE and Sonographic HS, the difference between the two ways of measuring head position was also not statistically significant across time points, demonstrating the consistency of sonographic findings. Ultrasound (US) Head-Perineum Distance was positively correlated with VE Fetal Head Station (P 0.001). No significant discrepancies were found between VE and Sonographic HP measured by the face clock technique at any of the time points studied, providing additional evidence for the reliability of sonographic results. Statistically significantly (P 0.001), TPUS had a much greater rate of female compliance and satisfaction than VE did (66.7% vs. 38.9%).

Sweed et al. found similar outcomes when they observed 40 first-time mothers in labour and assessed the efficacy of transperineal ultrasonography in tracking labour. Women in active labour (cervix 4-10 cm dilated) who were having their first child and were older than 18 years old and pregnant for the first

time were included in the research. Assessment of foetal head position by VE and foetal HPD by TPUS were shown to have a moderate association (Kendall's tau-b ( $\tau_b$ ) = 0.299, 95 percent CI = 0.479 to 0.0863, P-value = 0.0063). Cervical dilatation measured by VE and US is well correlated (Pearson's  $r = .8601$ , 95% CI = 0.7493 to 0.9240,  $p = .0001$ ,  $r^2 = 0.7396$ ). In terms of measuring cervical dilatation, VE and US yielded mean differences of 0.65 1.11 cm. 1.52 cm - 2.82 cm were the range of agreement. When comparing VE and US, the average discrepancy in foetal rotation evaluation on the face-clock was 0.65 2.38 h. The range of opinions was from -5.52 to -3.92 face-clock hours. Weighted kappa ( $\kappa_w$ ) = .557, 95% confidence interval (CI) = .362 to .753 indicates considerable agreement between VE and US in determining head position on the face-clock. Twenty-four out of forty (60%) female respondents reported being compliant with TPUS, however only fourteen out of forty (35%) reported being satisfied,  $p = 0.025$  [9].

Usman et al. compared the efficacy of vaginal examination with that of transabdominal and transperineal ultrasonography in determining the stage of labour. The foetal head position was documented by US in 99.7% (298/299) of pregnancies and by vaginal examination in 51.5% (154/299) ( $p = .0001$ ). In 96.3 percent (308/320) of VEs and 95.7 percent (307/320) of USs ( $p = .79$ ) [11], the head station was recorded.

Furthermore, there was a negative correlation between head station and head perineum distance (Spearman's  $r = -.57$ ,  $p = .0001$ ). Cervical dilation was measured by US in 54.4% (178/327) of cases, whereas VE/speculum was used in 100% of cases ( $p = .0001$ ). The head station of foetuses with caputs larger than 10 mm was substantially lower ( $p = .0001$ ). They detail labour room ultrasonography examinations that might be used to the evaluation of labouring mothers. Vaginal examination is not a reliable method for determining the foetal head position and has a poor correlation with US. Vaginal examination reveals a moderate association between foetal head position and the distance between the perineum and the cervix. Ultrasound is not a reliable method of assessing cervical dilation beyond 4 cm. It is possible to use transperineal ultrasonography in the delivery room, and the results are often more reliable than those of a vaginal assessment [11].

Hassan et al., the pioneers of non-invasive ultrasound (US)-based evaluation of labour

progress (the 'sonopartogram'), similarly explored the viability of this method for evaluating cervical dilation, foetal head drop, and foetal head rotation. Among the 20 women who participated in the research, the median ages were 34 (range, 21-41) years, 0 (range, 0-2), and 29 (range, 22-47) kg/m<sup>2</sup>. They also noted that the median number of weeks of pregnancy when participants were included in the research was 40 (range, 37-41).

Abd-alhady et al. also compared the efficacy of intrapartum sonography and digital vaginal examination in predicting labour progression during the first stage of labour. Eighty-six point one percent of the patients in that research had a vaginal birth, whereas nineteen point three nine percent have a CS delivery. Based on these findings, they concluded that ultrasonography may be used to aid in the prediction of vaginal birth success and the promotion of safe surgical delivery [13].

Our findings are supported by those of Yuce et al. [14], who compared the accuracy of digital vaginal examination (DVE) and ultrasonographic measurement of cervical dilatation and found that the former had a higher ICC (0.82) (95% CI [confidence interval]: 0.73-0.88), despite the latter's measurements being slightly smaller (by about 10 mm) than the former.

Several investigations demonstrated the difficulties and variations in precision inherent to digital evaluation of cervical dilation. Results from previous research comparing digital examination and physical examination of cervical dilation have been mixed. When accounting for a 1 cm discrepancy in cervical dilatation measurements, 90% agreement was found [15]. Complete agreement was seen in 42%-49% of instances.

Digital vaginal examination (DVE) accuracy was shown to be highest at the lower (1-4 cm) and higher (>8 cm) limits of the cervical dilatation scale, as reported by Nizard et al. When the cervix was completely dilated, the success rate was close to 75% [16].

Between 2017 and 2018, researchers in Egypt studied 600 pregnant women prospectively to determine the efficacy of transperineal USG in determining labour progression. Two categories of topics have been created. There were 300 women who made normal progress in labour and another 300 women whose first stage of labour was protracted. They found that AOP and HPD together and AOP alone were the most relevant indicators for predicting labour progress and method of delivery [17], concluding that USG is a useful tool.

Also, during the initial stage of labour, Karkour et al. studied 200 pregnant women (100 primigravidae and 100 multiparae) at El Shatby Hospital. Ultrasound was used to monitor the foetal head's descent, rotation, and cervical dilatation as labour progressed. This research showed that compared to the standard per-vaginal examination, ultrasonography gives more objective assessments of labour progress and better predicts delivery outcomes and neonatal abnormalities. Furthermore, ultrasonography was preferred by labouring women over a per-vaginal examination since it was less invasive and provided a more thorough evaluation [18].

Women have shown greater acceptability of TPUS for assessing labour progress compared to repeated VE. Hassan et al. sonopartogram 's improves upon the traditional partogram in terms of both accuracy and efficiency, allowing for more thorough monitoring of labouring mothers [12].

## 5. Conclusion

Transperineal One promising tool for monitoring the progress of labour in first-time moms is transvaginal ultrasonography (TPUS). Our findings demonstrate a strong correlation between TPUS measurements and standard vaginal exams at many stages of labour. These results support the use of TPUS to assess foetal head position, cervical dilation, and head station. There is also evidence that TPUS may make patients more comfortable during labour.

## References

- [1] G. Moncrieff, G.M. Gyte, H.G. Dahlen, G. Thomson, M. Singata-Madliki, A. Clegg, et al. Routine vaginal examinations compared to other methods for assessing progress of labour to improve outcomes for women and babies at term. *Cochrane Database Syst Rev*;3:Cd010088. 2022
- [2] Z. Mohaghegh, S. Jahanfar, P. Abedi, M.A.A. El Aziz. Reliability of ultrasound versus digital vaginal examination in detecting cervical dilatation during labor: a diagnostic test accuracy systematic review. *Ultrasound J*;13:37. 2021
- [3] S.A. Shazly, I.A. Ahmed, A.A. Radwan, A.Y. Abd-Elkariem, N.B. El-Dien, E.Y. Ragab, et al. Middle-East OBGYN Graduate Education (MOGGE) Foundation Practice Guidelines: Prelabor rupture of membranes; Practice guideline No. 01-O-19. *J Glob Health*;10:010325. 2020

- [4] J.H. Zafra-Tanaka, R. Montesinos-Segura, P.D. Flores-Gonzales, A. Taype-Rondan. Potential excess of vaginal examinations during the management of labor: frequency and associated factors in 13 Peruvian hospitals. *Reproductive Health*;16:1-8. 2019
- [5] A. Youssef, E. Brunelli, E. Montaguti, G. Di Donna, M.G. Dodaro, L. Bianchini, et al. Transperineal ultrasound assessment of maternal pelvic floor at term and fetal head engagement. *Ultrasound Obstet Gynecol*;56:921-7. 2020
- [6] T. Bultez, T. Quibel, P. Bouhanna, T. Popowski, M. Resche-Rigon, P. Rozenberg. Angle of fetal head progression measured using transperineal ultrasound as a predictive factor of vacuum extraction failure. *Ultrasound Obstet Gynecol*;48:86-91. 2016
- [7] Y.A. Wiafe, B. Whitehead, H. Venables, E.K. Nakua. The effectiveness of intrapartum ultrasonography in assessing cervical dilatation, head station and position: A systematic review and meta-analysis. *Ultrasound*;24:222-32. 2016
- [8] S. Usman, A. Hanidu, M. Kovalenko, W.A. Hassan, C. Lees. The sonopartogram. *Am J Obstet Gynecol* 115-17. 2023
- [9] M.S. Sweed, I.F. Allam, S.A. Ashoush, O.A. Marwan, E.A. NasrElDin. Sonopartogram versus conventional partogram for monitoring progress of labor: a prospective observational study. *Egyptian Journal of Radiology and Nuclear Medicine*;51:170. 2020
- [10] S.A. Solaiman, K.A. Atwa, A.A. Gad, M. al-Shatouri. Transperineal ultrasound of fetal head progression in prolonged labor: women's acceptance and ability to predict the mode of delivery. *Egyptian Journal of Radiology and Nuclear Medicine*;51:94. 2020
- [11] S. Usman, M. Wilkinson, H. Barton, C.C. Lees. The feasibility and accuracy of ultrasound assessment in the labor room. *J Matern Fetal Neonatal Med*;32:3442-51. 2019
- [12] W. Hassan, T. Eggebø, M. Ferguson, A. Gillett, J. Studd, D. Pasupathy, et al. The sonopartogram: a novel method for recording progress of labor by ultrasound. *Ultrasound Obstet Gynecol*;43:189-94. 2014
- [13] R.R. Abd-Alhady, M.R. Elsayed, E.N.A.-E. Sator, A.M. Sarhan. Intrapartum Sonography versus Digital Vaginal Examination in the First Stage of Labor for Prediction of the Progress of Labor. *Egypt J Hosp Med*;86:78-84. 2021
- [14] T. Yüce, E. Kalafat, A. Koc. Transperineal ultrasonography for labor management: Accuracy and reliability. *Acta Obstetrica et Gynecologica Scandinavica*;94:760-5. 2015
- [15] S. Benediktsdottir, T.M. Eggebø, K.Å. Salvesen. Agreement between transperineal ultrasound measurements and digital examinations of cervical dilatation during labor. *BMC Pregnancy and Childbirth*;15:273. 2015
- [16] J. Nizard, S. Haberman, Y. Paltieli, R. Gonen, G. Ohel, D. Nicholson, et al. How reliable is the determination of cervical dilation? Comparison of vaginal examination with spatial position-tracking ruler. *Am J Obstet Gynecol*;200:402. 2009
- [17] G.A. Ibrahim, A.S. Nasr, F. Atta, M. Reda, H. Abdelghany, N.M. El-Demiry, et al. The Assessment of intrapartum transperineal ultrasonographic parameters for their effectiveness in evaluation of progress of labor and prediction of mode of delivery in Egyptian women. *Open Access Macedonian Journal of Medical Sciences*;9:1037-43. 2021
- [18] T.A. Karkour, T. Abd Aldayem, T.M. Abd EL Aziz Ibrahim, J.M. El Baradei. Sonopartogram versus traditional partogram in the active phase of first stage of labor and correlation to outcome. *ALEXMED ePosters*;4:26-7. 2022